

## Hindlimb malformation in *Heremites vittata* Olivier, 1804 from Palestine (West Bank)

Elias N. Handal<sup>1,\*</sup> and Apostolos Christopoulos<sup>2</sup>

Limb malformations in reptilian groups have been recorded in several species of lizards and the few published reports mainly focus on abnormalities of digits (Kaliontzopoulou et al., 2013; Cortada et al., 2017; Itescu et al., 2017; Sanches et al., 2017) and legs (Norval et al., 2009; Gkourtsouli-Antoniadou et al., 2017; Kolenda et al., 2017). Even fewer documented reports focus on skink limbs (e.g., Christopoulos and Pafilis, 2020; Decemson et al., 2021). In skinks, other morphological anomalies have been reported mainly as bifurcated tails (Jablonski, 2016; Turner et al., 2017; Vergilov and Natchev, 2017; Handal, 2021) and kyphosis (abnormal spinal curvature of  $\geq 50^\circ$ ; Arrivillaga and Brown, 2019).

According to Christopoulos and Pafilis (2020), limb malformations in skinks from Europe are rare, with the exception of a case of the Ocellated Skink, *Chalcides ocellatus* (Forsskål, 1775), from Greece. Moreover, from Asia, Decemson et al. (2021) reported cases of two skink species with similar limb abnormalities. Another similar report by Skinner (2012) discussed malformations in the digits of skinks, but without mention of malformation of entire limbs. We here report a hind limb malformation in the Bridled Skink, *Heremites vittata* Olivier, 1804, from the Palestinian Territories.

*Heremites vittata* is a medium-sized skink (maximum snout–vent length, SVL 110 mm) with a wide distribution across North Africa and the Levant into Iraq, Iran, and Cyprus (Sindaco and Jeremčenko, 2008; Handal et al., 2016; Werner, 2016). In Palestine, this species is found in the northern part of the Negev Desert as far north as Jenin (Werner, 2016).

In 2021 the first author came across a specimen of *H. vittata* in the Herpetological Collection of the Palestine Museum of Natural History at Bethlehem University (PMNH), collected at Abu Dis (31.7517°N, 35.2623°E) on 22 April 2013. The specimen (PMNH-V151; SVL 86 mm, tail length 116 mm) had been found dead at the collection site. It presents with a malformation of the left hind limb (Fig. 1). An x-ray shows that the limb lacks most of the distal long bones (tibia and fibula; Fig. 2) with the exception of a short stub (length ca. 2 mm).


The most plausible scenario for the observed abnormality is that it is the result of severe mechanical trauma or amputation during a predatory attack. Such an injury causes an open wound and provides ample opportunities for bacterial or fungal infection, which results in further pathologies and irregular healing (e.g., Jacobson 2007; Warwick et al., 2013). A predator could also very simply remove a body part, such as a limb. Alternatively, serious limb malformation may also be rooted in genetic disorders (Olsson et al., 1996; Rothschild et al., 2012; Alibardi, 2017; Cortada et al., 2017) that may be exacerbated by sudden changes in incubation temperature during embryonic development (Osgood, 1978; Webb et al., 1983; Webb and Cooper-Preston, 1989; Idrisova, 2018). However, the likelihood of injury and disease is supported by the morphology of the remnant bones seen on the x-ray, which are expected to have a different morphology or be absent in the case of underlying genetic causes (Martín-del-Campo et al., 2019; Winchell et al., 2019).

**Acknowledgments.** We thank the team of researchers at the Palestine Institute for Biodiversity and Sustainability for its efforts in studying the biodiversity in Palestine and collecting important specimens. Our thanks go to Zuhair Amr (Jordan University of Science and Technology, Ar-Ramtha, Jordan) and Mazin Qumsiyeh (Bethlehem University, Bethlehem, Palestine) for reviewing and editing our manuscript. Special thanks are due to Prof. Saïd Nourir and Mohamed Wassim Hizem (Faculty of Sciences, Tunis El-Manar University) for the pre-peer review of the manuscript and to Hinrich Kaiser (Victor Valley College, Victorville, California, USA) and Saeed Hosseinian Yousefkhani (Damghan University, Damghan, Iran) for their very careful review and valuable comments. This

<sup>1</sup> Palestine Institute for Biodiversity and Sustainability, Palestine Museum of Natural History, Bethlehem University, Bethlehem, Palestine.

<sup>2</sup> Department of Zoology and Marine Biology, Faculty of Biology, National and Kapodistrian University of Athens, Panepistimioupolis, 15784 Athens, Greece.

\* Corresponding author. E-mail: eliashandal93@gmail.com

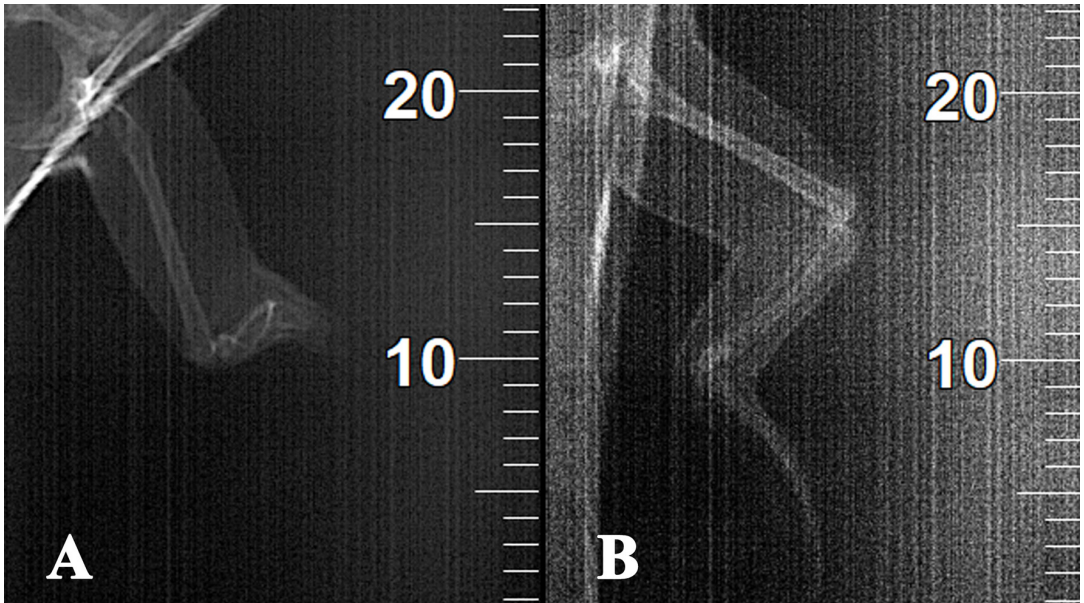


**Figure 1.** A specimen of *Heremites vittata* (PMNH-V151) from Palestine, presenting a malformation on the left hind limb. (A) The entire specimen in ventral view. (B) Dorsal view. (C) The malformed left hind limb in posterolateral view. (D) The normal right hind limb. Scale bars = 10 mm, the shorter bar applicable to (A) and (B) and the longer one to (C) and (D). Photos by Elias Handal.

research was funded by a EUPI grant (ENI/2019/162124/83) under the program Unity and Diversity in Nature and Society at the Palestine Institute for Biodiversity and Sustainability (PIBS).

## References

- Alibardi, L. (2017): Review: biological and molecular differences between tail regeneration and limb scarring in lizard: an inspiring model addressing limb regeneration in amniotes. *Journal of Experimental Zoology B: Molecular and Developmental Evolution* **328B**: 493–514.
- Arnold, E.N. (1984): Evolutionary aspects of tail shedding in lizards and their relatives. *Journal of Natural History* **18**(1): 127–169.
- Arrivillaga, C., Brown, T.W. (2019): Kyphosis in a free-living *Marisora brachypoda* (Squamata: Scincidae) from Utila Island, Honduras. *Herpetological Bulletin* **148**: 43–44.
- Christopoulos, A., Pafilis, P. (2020): Hindlimb malformation in a widely distributed skink, *Chalcides ocellatus*. *Herpetology Notes* **13**: 15–17.
- Cortada, A., Kaliontzopoulou, A., Mendes, J., Carretero, M.A. (2017): A case of limb regeneration in a wild adult *Podarcis lilfordi* lizard. *Turkish Journal of Zoology* **41**: 1069–1071.
- Decemson, H., Vabeiryureilai M., Lalremsanga, H.T. (2021): First report on limb anomalies in *Sphenomorphus indicus* (Gray, 1853) and *Sphenomorphus maculatus* (Blyth, 1853) at the Dampa Tiger Reserve in Mizoram, India. *Sauria* **43**(3): 69–72.



**Figure 2.** X-rays of a malformed specimen of *Heremites vittata* (PMNH-V151) from Palestine. (A) The malformed, left leg, showing only a fragment (ca. 2 mm length) of the distal long bones. (B) The normal, right leg, showing the regular length of the distal long bones to be ca.10 mm.

- Gkourtsouli-Antoniadou, I., Deimezis-Tsikoutas, A., Vassaki, K., Vezyrakis, A., Pafilis, P. (2017): A tail where it shouldn't be: a morphological anomaly in *Podarcis erhardii*. *Herpetology Notes* **10**: 233–234.
- Handal, E.N. (2021): Tail malformation in *Ablepharus rueppellii* (Reptilia: Scincidae) from Occupied Palestine. *Jordan Journal of Natural History* **8**: 51–53.
- Handal, E.N., Amr, Z.S., Qumsiyeh, M.B. (2016): Some records of reptiles from the Palestinian Territories. *Russian Journal of Herpetology* **23**(4): 261–270.
- Idrisova, L.A. (2018): The effect of incubation temperature on deviations of pholidosis and malformations in grass snake *Natrix natrix* (L. 1758) and sand lizard *Lacerta agilis* (L. 1758) in the Second International conference “Amphibian and reptiles anomalies and pathology: methodology, evolutionary significance, monitoring and environmental health”, KnE Life Sciences **2018**: 70–74.
- Itescu, Y., Lewin, A., Slavenko, A., Meiri, S., Pafilis, P. (2017): Natural history notes. *Podarcis erhardii* (Erhard's Wall Lizard). Extreme morphology. *Herpetological Review* **48**(1): 199–200.
- Jablonski, D. (2016): Tail bifurcation in a Desert Lidless Skink (*Ablepharus deserti*) from Kyrgyzstan. *Reptiles & Amphibians* **23**(3): 171–172.
- Jacobson, E.R. ed., 2007. *Infectious diseases and pathology of reptiles: color atlas and text*. Boca Raton, Florida, USA, CRC Press.
- Kaliontzopoulou, A., Salvi, D., Gomes, V., Maia, J.P.M.C., Kaliontzopoulos, P. (2013): Polydactyly in the Tyrrhenian Wall Lizard (*Podarcis tiliguerta*). *Acta Herpetologica* **8**(1): 75–78.
- Kolenda, K., Wieczorek, M., Najbar, A., Najbar, B., Skawiński, T. (2017): Limb malformation and tail bifurcation in sand lizards (*Lacerta agilis*) and common lizards (*Zootoca vivipara*) from Poland. *Herpetology Notes* **10**: 713–716.
- Martín-del-Campo, R., Sifuentes-Romero, I., García-Gasca, A. (2019): Hox genes in reptile development, epigenetic regulation, and teratogenesis. *Cytogenetic and Genome Research* **157**(1–2): 34–45.
- Norval, G., Mao, J.J., Bursey, C.R., Goldberg, S.R. (2009): A deformed hind limb of an invasive free-living brown anole (*Anolis sagrei* Duméril & Bibron, 1837) from Hualien City, Taiwan. *Herpetology Notes* **2**: 219–221.
- Olsson, M., Gullberg, A., Tegelström, H. (1996): Malformed offspring, sibling matings, and selection against inbreeding in the Sand Lizard (*Lacerta agilis*). *Journal of Evolutionary Biology* **9**(2): 229–242.
- Osgood, D.W. (1978): Effects of temperature on the development of meristic characters in *Natrix fasciata*. *Copeia* **1**: 33–47.
- Rothschild, B.M., Schultze, H.-P., Pellegrini, R. (2012): *Herpetological Osteopathology*. Annotated Bibliography of Amphibians and Reptiles. New York, USA, Springer. 450 pp.
- Sanches, P.R., Santos, F.P., Costa-Campos, C.E. (2017): Ectrodactyly of the exotic lizard *Hemidactylus mabouia* (Gekkonidae) in an urban area of northern Brazil, eastern Amazon. *Boletín de la Asociación Herpetológica Española* **28**: 11–12.
- Skinner, A. (2012): Limb abnormalities in two species of *Lerista* (Scincidae, Squamata). *Current Herpetology* **31**: 1–7.
- Sindaco, R., Jeremčenko, V.K. (2008): *The Reptiles of the Western Palearctic, Volume 1. Annotated Checklist and Distributional*

- Atlas of the Turtles, Crocodiles, Amphisbaenians and Lizards of Europe, North Africa, Middle East and Central Asia. CITY, Italy, Edizioni Belvedere. 579 pp.
- Turner, H., Griffiths, R., Garcia, G., Outerbridge, M. (2017): Natural history notes. *Plestiodon longirostris* (Bermuda skink). Tail bifurcation. *Herpetological Review* **48**(1): 198–199.
- Vergilov, V., Natchev, N. (2017): First record of tail bifurcations in the snake-eyed skink (*Ablepharus kitaibelii* Bibron & Bory de Saint-Vincent, 1833) from Pastrina Hill (northwestern Bulgaria). *Arxius de Miscellània Zoològica* **15**: 224–228.
- Warwick, C., Arena, P., Lindley, S., Jessop, M., Steedman, C. (2013): Assessing reptile welfare using behavioural criteria. In *Practice* **35**(3): 123–131.
- Webb, G.J., Cooper-Preston, H. (1989): Effects of incubation temperature on crocodiles and the evolution of reptilian oviparity. *American Zoologist* **29**(3): 953–971.
- Webb, G.J.W., Sack, G.C., Buckworth, R., Manolis, S.C. (1983): An examination of *Crocodylus porosus* nests in two northern Australian freshwater swamps, with an analysis of embryo mortality. *Australian Wildlife Research* **10**(3): 571–605.
- Werner, Y.L. (2016): *Reptile Life in the Land of Israel, with Comments on Adjacent Regions*. Frankfurt am Main, Germany, Edition Chimaira. 494 pp.
- Winchell, K.M., Briggs, D., Revell, L.J. (2019): The perils of city life: patterns of injury and fluctuating asymmetry in urban lizards. *Biological Journal of the Linnean Society* **126**(2): 276–288.